# Chapter Review Answer Keys

## CHAPTER 1

### Terminology Review

1. _ B _ One of the four pillars of successful medical practice
2. _ A _ A system of diagnosis classification used in charting at hospitals
3. _ E _ One common approach to consistent medical record-keeping
4. _ C _ Diagnostic codes most commonly used in Western medical settings and for third party payers.
5. _ D _ A comprehensive nomenclature now becoming widespread, not for billing but for research, databases, trials.

A. DRG B. Timely referral of red flag cases

C. ICD-9 or 10 D. SNOMED E. SOAP

## CHAPTER 2

### Chapter Review

**1.** What are the six components of a complete medical history?

**1) CC:** chief complaint **2) HPI:** history of the present illness

**3) PMH:** past medical history **4) FH:** family history

**5) Psych (Ψ):** psychosocial history **6) ROS:** eview of symptoms

**2.** Can you name the seven parts of the history of present illness (HPI)?

**L:** Location: where is it; where does it radiate?

**Q:** Quantity: how strong or intense is it?

**Q:** Quality: what is it like? If the symptom is pain, is it stabbing, boring, aching, burning, or throbbing? The patient may come up with other descriptors.

**T:** Timing: does it come and go? How long have you experienced it? What time of the day is it better or worse?

**S:** Setting: what conditions bring it on (activities, stress, eating, etc.)

**F:** Factors making it better or worse

**A:** Accompanying symptoms or experiences

**3.** What are the CAGE questions? What are they designed to determine?

**C:** Have you ever felt the need to *cut down* on your drinking?
**A:** Have you ever felt *annoyed* by others criticizing you about your drinking?
**G:** Have you ever felt *guilty* about your drinking?
**E:** Have you ever taken an *eye opener* drink first thing in the morning to get over a hangover or to steady your nerves?

These questions are designed to determine is a person has a serious or health-threatening alcohol problem.

**4.** What is the definition of claudication? What does it suggest to you in terms of Chinese pattern differentiation?

Claudication is an aching, crampy, tired, and sometimes burning pain in the legs that comes and goes (it typically occurs with walking and goes away with rest) due to poor circulation of blood. In Chinese medical theory, we would consider both qi and blood vacuity weakness, kidney yin vacuity, damp heat, and blood stasis as possible likely patterns to present in this disease.

**5.** Looking at the review of symptoms (ROS), what are the three major categories of symptoms that need to be collected?

General constitutional, psychiatric, and specific organ-related symptoms.

**6.** If your patient states that they have difficulty swallowing, what are a couple of follow-up questions that you might ask?

a. Have you had any imaging studies of your throat and esophagus? (This is to rule out a benign or cancerous growth and should be done if it has not.)

b. Do you feel this feeling all the time, or does it come and go? (If it comes and goes, this suggests that this is "plum-pit qi" according to OM diagnosis, in which case, you would want to corroborate the presence of other signs and symptoms of phlegm and liver depression qi stagnation.)

**7.** What does a chart notation of Gr4 P3 Ab1 mean?

It means four pregnancies, three live births, and one abortion.

**8.** Name three gastrointestinal symptoms that might cause you to send a patient for Western medical tests or further evaluation? In each of the three cases, explain why.

a. Rectal bleeding: this may be due to lower GI cancer.

b. Jaundice: this may be due to liver or gallbladder disease.

c. Severe, unremitting abdominal pain: this could be due to a wide variety of life-threatening conditions.

d. Vomiting of blood: could be due to cancer or peptic ulcers in the stomach or duodenum.

**9.** A good history and PE are important because they may eliminate the need for what?

These may eliminate the need for expensive and potentially dangerous or painful tests or imaging studies.

**10.** The ROS is similar to what process in Chinese medical diagnosis? What are the exact areas of overlap?

The ROS is similar to Zhang Jing-yue's Ten Questions of Chinese medical examination and diagnosis, overlapping in the areas of body temperature, unusual perspiration, any body pain, symptoms in the chest and abdomen, symptoms of defecation and urination, appetite and digestion, hearing and vision, and the history of gynecological problems. The tenth question that relates to the history of the present disease is almost exactly like the HPI in a Western medical history.

## CHAPTER 3

### Chapter Review

**1.** What are the four components of taking a patient's vital signs?

This includes temperature, respiration rate (note if there is difficulty breathing) heart rate (in Western medical workups this is recorded as pulse quality, rhythm, and rate), and blood pressure.

**2.** What are the things you look for when assessing a patient's general appearance?

You should note the patient's general appearance: height, weight, build, complexion, dress and neatness, level of alertness and energy, your impression of a healthy state versus one of acute or chronic illness, problems with ambulation, demeanor, sense of cooperation, diminished agility or coordination.

**3.** For a patient who seems to have diminished agility and coordination, what further type of exam will be important?

A general, thorough neurological exam.

**4.** What is the highest mmHg to pump the cuff that is tight enough but not painful when taking a blood pressure?

Over 180 mm Hg is painful on the arm. Inflate the cuff until the pulse is obliterated. No higher is necessary.

**5.** The antecubital (elbow) crease should be kept at what height on the patient's torso when taking a blood pressure?

No higher than the level of the heart or the 4th-5th interspace.

**6.** What body position is best for taking a blood pressure: standing, seated, or lying down?

You can take the blood pressure in any of these positions as long as the arm is relaxed and antecubital fossa is easily available and no higher than the heart.

**7.** Which direction should the stethoscope go into the practitioner's ear and why?

The ear-pieces of the stethoscope should be angled forward, as this is the direction of the ear canals.

**8.** Reducing the pressure by 2-3 mmHg per second, the SYSTOLIC pressure is the higher number that you first hear when the vessel is no longer completely occluded by the cuff.

**9.** If a patient has drug-induced postural hypotension, taking their blood pressure in which position is likely to give the lowest reading?

In such patients, the systolic pressure may fall about 5mm when patients are in the standing position.

**10.** In what common disease might there be a significant difference right to left in the blood pressure when a reading is taken on both sides? What would such a difference potentially indicate?

Vascular disease, which should be referred as a subacute red flag if the patient is unaware of it, could be a cause of this situation

## CHAPTER 4

### Chapter Review

**1.** What is the most common location of skin cancer?

The tops of the ears.

**2.** A healthy ear drum or tympanic membrance should appear_____, _____, and slightly _____?

Concave, semi-transparent, and slightly shiny.

**3.** What is the meaning of conjugate gaze?

That the pupils of both eyes move together when scanning in any direction.

**4.** What are xanthalasthmas and what do they indicate?

These are small yellow fatty deposits under the eyes of some people who have lipid abnormalities.

**5.** White lesions on the sides of the tongue that do not easily scrape off are called _____?

Leukoplakia.

**6.** The uvula is _____?

The fleshy projection that hangs down in the center at the back of the mouth.

**7.** Enlarged lymph nodes are a minor red flag because _____.

They can be an indication of inflammation or cancer affecting some part of the head, neck, or other organs.

**8.** The submental nodes should or should not be palpable?

These should not normally be palpable.

**9.** A tongue body that is pulling to one side in Chinese medicine indicates internal wind. In Western medicine, it indicates dysfunction in which of the cranial nerves?

The hypoglossal nerve (#XII) controls movement of the tongue.

10. The job of the turbinates inside the nose is to do what?

Warm, moisten, and clean the air entering through the nose before it goes into the lungs.

## CHAPTER 5

### Chapter Review

1. What are the four basic methods used to examine the chest and lungs?

Inspection, percussion, palpation, and auscultation.

2. Retraction of the intercostal spaces with breathing suggests what about the lung tissue?

Suggests both poor compliance and elasticity of the lungs tissues so that they don't expand easily.

3. If you suspect lung disease of any serious or chronic nature, what unusual sign should you look for?

Clubbing, a curious widening of the fingertips seen in those with chronic lung problems, also causes a flattening of the angle the fingernail makes when it inserts into the finger.

4. How many ribs articulate with the sternum? Which ones?

The first seven ribs articulate with the sternum.

5. How many ribs are floating? Which ones?

The 11th and 12th ribs are floating.

6. What is the location and description of the sternal angle (Angle of Louis)?

The sternal angle is a horizontal ridge where the manubrium of the sternum meets the body of the sternum. It is about 5 cm below the sternal notch at the base of the neck.

7. At expiration the lower border of the lungs is at the 6TH rib level at the mid-clavicular line and the 8TH rib at the mid-axillary line. Posteriorly, it is at about the 10TH thoracic spinous process.

8. When breathing in the diaphragm ascends or descends?

It descends when breathing in.

9. FREMITUS is the vibration of vocal sounds transmitted through the lungs to your hands when you ask the patient to say, "ninety-nine." Feel for it over the UPPER MEDIAL back on both sides.

10. Bronchial breath sounds are only normal when heard over the manubrium where the TRACHEA is located.

### Terminology Review

| | | |
|---|---|---|
| 1. b | 4. a | 7. c |
| 2. g | 5. f | 8. d |
| 3. e | 6. h | |

## CHAPTER 6

### Chapter Review

1. The aortic valve is in the 2ND interspace on your left (the patient's right).
2. The apical pulse, sometimes called the PMI (point of maximum impulse), which in the normal-size heart is in the 5TH interspace just medial to the MID-CLAVICULAR line.

3. Keep the patient supine for listening to the AORTIC, PULMONARY, and tricuspid valves. The MITRAL valve is best heard with the patient in lateral decubitus position.
4. The softer lubb is mostly the sound of the MITRAL valve closing (with a bit of the tricuspid valve behind it) and the sharper sounding dupp is mostly the AORTIC valve snapping shut against the systolic pressure of 120 mm Hg in the aorta, with a bit of the pulmonic valve behind it.
5. The softer "lubb" or 1st sound is called **S1** The "dupp" snap, or 2nd sound is known as **S2** . It is actually the aortic and pulmonic valves closing together.
6. Aortic stenosis and mitral valve regurgitation are two types of PATHOLOGIC SYSTOLIC heart murmurs.
7. There are no "innocent" DIASTOLIC murmurs. They almost always indicate heart disease.
8. Patent ductus arteriosis (PDA) causes a harsh and loud sound, heard best at the 2ND interspace on the LEFT side.
9. Mitral regurgitation is an even-toned, holosystolic murmur heard best at the APEX OF THE HEART (5th interspace at the mid-clavicular line).
10. Hyperdynamic blood flow murmurs are also heard in those who are pregnant, anemic, are hyperthyroid, or have a fever. These murmurs indicate A HEALTHY ACTIVE HEART THAT IS WORKING HARD.

## Anatomy Review

Match the anatomical body parts to the numbers shown on the heart.

Superior vena cava _4_
Aorta _1_
Pulmonary valve _2_
Right atrium _3_
Right ventricle _10_
Left atrium _6_
Left ventricle _8_
Aortic valve _7_
Pulmonary artery _5_
Inferior vena cava ___

## CHAPTER 7

### Chapter Review

### Part 1. Quiz

1. We traditionally stand on the patient's RIGHT side for the abdominal exam.
2. Name four landmarks we will take note of to start our abdominal exam.

Xiphoid process, umbilicus, pubis, iliac crest, and costal margins as well as the anterior iliac spines and McBurney's Point are all possible landmarks.

3. The right lower quadrant is generally the best place to listen for BOWEL SOUNDS because the other quadrants have SOLID ORGANS THAT MAY INTERFERE WITH LISTENING.
4. The normal frequency of peristaltic sounds is **5-TO-30** sounds per minute.
5. Bowel sounds are decreased in a patient who has an adynamic ileus. This is a condition that occurs under what types of circumstances?

After surgery, as a side effect of certain medications, or with early peritonitis from a ruptured appendix, perforated ulcer, ruptured gallbladder, pancreatitis, or some other cause.

6. A completely silent abdomen with no bowel sounds occurs in what situation?

Full onset of peritonitis.

7. Aortic bruits are heard in the mid-abdomen just below the umbilicus, suggesting ADVANCED AORTIC ATHEROSCLEROSIS.
8. Hypertension caused by RENAL ARTERY STENOSIS is potentially curable, as opposed to essential hypertension, which is treatable but not curable.
9. The normal aorta in the abdomen is approximately **2.5-3** CM wide.
10. Explain how to locate McBurney's point. If palpation of this point is not clear, what other tests can be used to corroborate appendicitis?

It is found one-third the way from the anterior superior iliac spine (ASIS) on a line from the ASIS to the umbilicus.

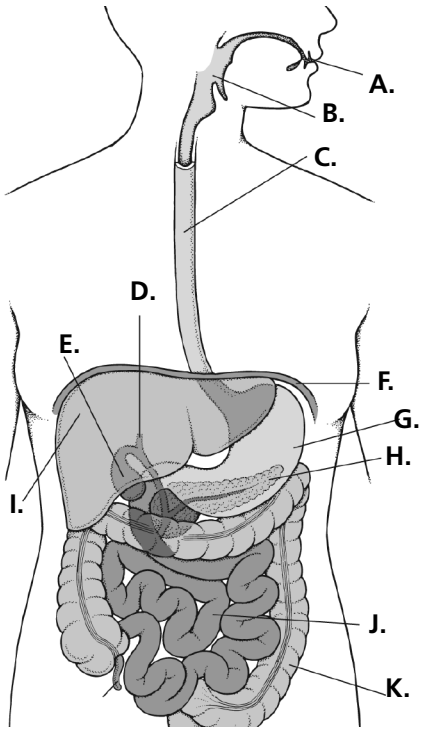


## PART 2. MATCHING

Name each structure and match the letter with the appropriate sentence below. Some may be the correct answer more than once.

1. Organ most related to ascites. **I.**
2. Organ which secretes bile. **E.**
3. Organ which should, from top to bottom, be about the width of your hand. **I.**
4. Organ over which you should be able to hear regular gurgles/squeaks and which should never be silent. **J.**
5. These three are the first parts of the alimentary canal. **A., B., C.**
6. Tube or channel via which bile is secreted. **D.**
7. Organ containing the Isles of Langerhans. **H.**
8. Area where one may find dullness and solidity upon percussion if there is gastric carcinoma. **G.**
9. Muscular membrane that expands and descends during breathing. **F.**

## PART 3. REVIEW OF ABDOMINAL ANATOMY

| Structure or Organ | Quadrant | Region |
|---|---|---|
| Spleen | ULQ | epigastric |
| Stomach | UL & URQ | epigastric |
| Liver | URQ | epigastric |
| Bile duct | URQ | epigastric |
| Diaphragm | UL & URQ | epigastric |
| Appendix | LRQ | hypogastric |
| Pancreas | UL & URQ | epig. & periumbilical |
| Navel | Dividing line for all four | umbilical |
| Small intestine | LR & LLQ | periumbilical |
| Transverse colon | UR & ULQ | epigastric |

Keep in mind that some of these may be found in more than one region or quadrant.

## CHAPTER 8

### Chapter Review

### Part 1: Quiz

1. There are three types of joints: fibrous, CARTILAGINOUS, and SYNOVIAL.
2. What is the function of elastohydrodynamic lubrication in the joints?

Elastohydrodynamic lubrication resists excessive wear or any change in the shape of the joint surface when the joint is under maximum stress. This confines the stress and friction and protects against damage to the joint.

3. There are potentially ten or more abnormalities that you are looking or testing for in a musculoskeletal and joint exam. Please name at least five of these.

These abnormalities could inclue any of the following:

- Abnormal posture, as in someone with Parkinson's disease (they have a simian-like stooping posture with advanced disease)
- Limitation of range of motion, or, in unusual cases, hyper-motility of range of motion
- Tenderness over the area or pain upon movement
- Redness in the area being studied
- Swelling in this area
- Increased heat in the area being tested
- Any contractures of joints
- Weakness of muscular strength
- Atrophy of the muscles in the area
- Asymmetry, possibly suggesting a stroke, injury, or other neuromuscular abnormality

4. The three normal curves of the spine are the cervical LORDOSIS, the thoracic KYPHOSIS, and the lumbar LORDOSIS.
5. Forward flexion of the neck should be approximately 90 degrees; backward flexion should be approximately 30 degrees.
6. Four common possible dysfunctions or malformation of the feet and toes include BUNIONS, HAMMER TOE, MORTON'S NEUROMA, and PLANTAR FASCIITIS.
7. A collection of fluid in a joint, which can often be palpated as a fullness and can build up in the joint if there is inflammation (arthritis) or injury, is called an EFFUSION.
8. Bend and extend each knee joint and check it for LAXITY (THE DRAWER SIGN) or LOCKING AND CATCHING suggesting a possible meniscus tear.
9. A positive Lasseg's sign confirms what Western diagnosis? SCIATIC NERVE ROOT COMPRESSION
10. The drawer sign in examining the knee means that which ligaments are compromised? ANTERTIOR AND POSTERIOR CRUXIATE LIGAMENTS

## PART 2: TERMINOLOGY REVIEW

Match the following terms with the statements below.

| | |
|---|---|
| 1. Cartilaginous joints | 2. Synovial membrane |
| 3. Squeeze film | 4. Kyphosis |
| 5. Joint effusion | 6. Drawer sign |
| 7. Lasseg's sign | 8. Scoliosis |
| 9. Fibrous joints | 10. Straight leg sign |

**2.** A highly-vascular and flexible structure, which secretes a joint lubricating fluid to reduce friction

**9.** Examples of this type of joints include the bones of the cranium, the pelvis, and the distal tibial-fibular joint.

**7.** A test in which the practitioner dorsiflexes the foot at the top of the patient's fullest possible leg extension, to determine sciatic nerve irritation or compression.

**5.** A collection of fluid in a joint, often seen when arthritis is present

**4.** The normal backward curvature of the thoracic spine

**6.** A test that shows loss of stability in the ligaments of the knee

**1.** These joint membranes are at the ends of the bones and are covered with hyaline cartilage supported by fibrous ligaments.

**3.** A boundary lubricant that is released from within the surface of the cartilage to cope with greater stress

**10.** A test ued to determine the presence and severity of sciatic nerve compression

**8.** An abnormal lateral curvature of any section of the spine

## CHAPTER 9

### Chapter Review

### Part 1: Quiz

1. List the six components of the neurological exam.

1. The mental status exam
2. Cranial nerve exam
3. Motor exam
4. Deep tendon reflex testing
5. Coordination and gait assessment
6. Sensory testing

2. In the mental status exam, what are the questions you might ask to determine delusions?

You may ask the patient, "Do you have special powers?" or "Is someone out to get you?"

3. Describe the difference between an hallucination and an illusion.

Hallucinations are perceptions in the absence of stimuli (seeing something that is not there). Illusions are misperceptions of sensory stimuli (seeing a coat hanging in a darkened hallway as an intruder).

4. Describe the parts of the MMSE and how it is scored.

- 10 points for varying degrees of orientation in time and space (where are you; what is the date and day of the week?)
- 5 points for concentration. Ask the patient to spell WORLD backwards or count back from 100 by 7's. Have the patient say, "No ifs, ands or buts!"
- 3 points for correctly naming three objects in the room.
- 3 points for naming two objects the patient saw earlier today that are not in the room (not presently in view).
- 3 points for following a 3-step command in sequence: stand up, raise your hands over your head, and turn completely around one time.

- 3 points for following a double command: "close your eyes and put your hands over your closed eyes"; "pick up this pencil and write a sentence on this piece of paper."
- 3 points for recalling the 3 objects you asked them to name earlier in the test

Total: 30 points (29 is also normal). College graduates average 28-29. Below 25 is distinctly abnormal.

5. What are the 12 cranial nerves in order?

| | |
|---|---|
| I – Olfactory | VII – Facial |
| II – Optic | VIII – Auditory (or vestibulocochlear) |
| III – Oculomotor | IX – Glossopharyngeal |
| IV – Trochlear | X – Vagus |
| V – Trigeminal | XI – Spinal accessory |
| VI – Abducens | XII – Hypoglossal |

6. What areas of the face do the three branches of the trigeminal nerve affect?

V1 – anterior scalp and forehead; V2: cheek; V3: jaw and underside of chin.

7. Name the two divisions of the acoustic or auditory nerve.

1. The cochlear nerve controls hearing acuity; 2. the vestibular nerve controls balance.

8. Muscular dystrophy is a disease affecting which part of the neuromuscular or motor system?

This is a lower motor neuron disorder.

9. In the motor exam, all muscle groups need to be checked for what four things?

Bulk, tone, strength, and dexterity of movement.

10. When testing for muscle strength, it is important to know which spinal segment is being affected. How many of the muscle groups and corresponding spinal segments can you name?

Here are the subgroups:

- muscles of the neck, shoulders, upper arms, forearms, wrists, fingers, and cervical spinal segments
- muscles of the torso, both stomach and back musclesl thoracic spine segments
- muscles of the buttocks, hips, thighs (quadriceps and hamstrings), calves, ankles, toes, and lumbar spinal segments.

11. The deep tendon reflexes in which four places on the body?

| | |
|---|---|
| Achilles reflex: S1, S2 | Patellar reflex: L3, L4 |
| Biceps reflex: C5, C6 | Triceps reflex: C7, C8 |

12. Can you discuss the possible causes of hyper-reflexia in all the deep tendon reflexes?

This is usually due to a generalized central nervous system disease, which could be neoplastic, degenerative (as with ALS), inflammatory (encephalitis; brain abscess), vascular (after a stroke, for example), or post-traumatic.

13. Describe the Romberg Test. This test is included in what part of the six sections of the neurological exam?

Ask the patient to stand with her feet right together and look for balance problems or swaying, noted in those who have cerebellar or labyrinthine disease. Then ask the patient to close her eyes and stand still. The patient sways widely or moves feet for balance if she has posterior column disease. this test is part of the cerebellar functioning or gait and coordination test.

14. The cerebellar function tests are called by what other name? Can you describe several manifestations of cerebellar dysfunction?

They are also called gait and coordination tests. The cerebellum integrates information from the sensory and motor parts of the nervous system to achieve fluid, coordinated motion, a perfectly balanced posture (not the same as sense of balance with different body positions in space, which is labyrinthine control) and speech. Disorders result in gait problems, speech difficulties, abnormal eye movements, tremors, and excessive clumsiness.

15. What are the two parts of the sensory exam? Can you think of particular patient situation or group of symptoms a patient could report in which you would want to perform this exam?

Part 1 of this exam tests the primary sensations of pain, temperature, joint position, vibration, and light touch. Part 2 tests cortical sensations such as two point discrimination, stereognosis (ability to recognize objects by their shape) and graphesthia (the ability to recognize letters and numbers drawn on the palm of the hand, for example.)

## CHAPTER 10

### Chapter Review

1. Name three skin conditions on this list that do not usually require treatment and are not diagnostically significant.

Port-wine stain, freckles, and macules scars and keloids may or may not be diagnostically significant and may or may not require treatment. Hemangiomas and macules are diagnostically significant from a Chinese medical point of view (supporting a pattern discrimination of blood stasis), but they, themselves, do not require treatment.

2. List at least two skin conditions described here that would cause you to send a patient to a dermatologist for evaluation.

Melanomas and impetigo. You might also make a case for such a referral with several other conditions, including lichenification, excoriation, decubitus ulcers, or in cases of bullas over a large area of the body.

3. List at least two skin conditions described here that you think would respond well to Chinese medical treatment.

Wheals or urticaria due to allergies can be well treated by Chinese medicine, as can eczema. Certain types of bullas, erosion, and possibly atrophic skin could be improved through Chinese herbal medicine.

4. Describe the possible Chinese medical pathomechanisms that could describe urticaria.

Urticaria are red, raised, and itchy. While there could be several complex disease mechanism involved from a Chinese medical point of view, we can say for sure that there is heat, wind, and possibly dampness all involved in this disorder. There is usually also spleen qi vacuity leading to a defensive qi vacuity involved in most respiratory and skin allergies, all of these mecha-

nisms being complicated by liver depression with depressive heat or by liver kidney yin vacuity with vacuity heat.

5. What is the Chinese medical pattern used to describe what Western medicine calls a nodule (fibroma, lipoma, etc.)

Phlegm nodulation would be the appropriate pattern discrimination.

6. If a patient has serious signs of excoriation on any part of their body, to what specialist might you refer this patient? What other types of questions might you ask this patient?

You might suggest that the person see a psychotherapist or a psychiatrist if the person is seriously damaging him/herself. You might want to do a neurological exam or ask about other obsessive repetitive habits.

7. Name two synonyms for eczema.

This is simply called a rash or dermatitis.

8. Small nodules called erythema nodosum often appear on what part of the body?

On the shins or edge of the tibia.

9. What are telangiactasia? Can you describe them in Chinese medical terms? What might be the pathomechanisms leading to this condition?

These are dilated blood vessels within the skin with a twisted appearance, blanch with pressure, easily distinguished from veins visible under the skin. The are similar to spider nevi.

10. Lichenification that is yellowish-white, scaly, and itchy would lead you to try and corroborate what Chinese pattern discrimination?

Wind cold or wind heat with blood and possible yin vacuity and dryness.

## CHAPTER 11

### Chapter Review

1. What are the two generic categories of red flag cases? How should each one be handled?

Acute and subacute red flags. Acute red flags need to be referred to an emer-

gency room. subacute red flags need to be sent to an MD or appropriate Western medical care giver within a few days.

2. What are the main symptoms of pneumothorax? What are the physical findings with palpation and auscultation?

The patient may experience chest pain and dyspnea. On physical exam, there are asymmetrical breath sounds, normal on the unaffected side of the chest and almost absent on the side of the collapse. This area of pneumothorax is also hyper-resonant to percussion (drum-like).

3. What are the non-emergent causes of chest pain? Name at least four.

Muscle strain, chronic or paroxysmal cough due to bronchitis, costochondritis, esophageal spasm, pleurisy after pneumonia, or heartburn.

4. What are the life-threatening causes of chest pain?

Coronary artery occlusion due to a myocardial infarction, calcific aortic stenosis, pulmonary embolism, dissecting thoracic aneurysm, and a pneumothorax.

5. Name five or six possible signs and symptoms of an acute myocardial infarction.

Crushing chest pain, spontaneous sweating, shortness of breath, sudden onset of weakness, heart palpitations, and vomiting.

6. Vomiting can be a symptom of myocardial infarction. What other acute or life-threatening conditions can lead to vomiting?

Strokes, serious falls or other kinds of severe trauma.

7. What are three major signs to look for when doing a physical exam to confirm or deny a myocardial infarction?

Sweatiness or clamminess, a gallop rhythm of the heart upon auscultation, crackles in the lungs, low blood pressure, and shortness of breath.

8. Describe the mechanism by which calcific aortic stenosis bring on an acute myocardial infarction.

This starts with a thickening of the aortic valve due to the buildup of scar tissue, which then attracts the deposition of calcium. This thickening causes

a narrowing of the blood flow across the valve, eventually leading to coronary insufficiency and chest pain, which can bring on a myocardial infarction.

9. Aortic stenosis is most commonly seen in men or women? After what age?

Most often seen in women over 70 years of age.

10. Dissecting throacic aneurysm is most common in men or women? Over what age?

It is most often seen in elderly male patients over age 60, especially among those who have hypertension.

11. Name several possible situations that can lead to a DVT causing pulmonary embolism (PE).

Post-operative patients who are bed-ridden for a length of time are at risk, especially if the operation was lengthy. It is also seen in women immediately following childbirth. Metastatic cancer patients often have hyper-coaguability of their blood, which predisposes them to pulmonary emboli. Anyone is at risk after a long car or plane trip, especially if obese or elderly.

12. A blood clot due to PE causes the release of which vasoactive chemicals? This may lead to what condition in the patient?

Serotonin, prostaglandins, and bradykinins, which can put a patient into shock.

13. What is the difference between orthopnea and paroxysmal nocturnal dyspnea?

Orthopnea is difficulty breathing while lying flat. Paroxysmal nocturnal dyspnea is trouble breathing when sleeping at night. A form of orthopnea, this difficulty is associated with the early phase of heart failure.

14. What is the difference between bronchospasm and stridor?

Bronchospasm occurs in asthma and is expiratory wheezing. Stridor or croup, is inspiratory spasm or obstruction to a major airway. Stridor often sounds like the honking of a Canadian goose .

15. If tachypnea means rapid breathing, what does tachycardia indicate?

Rapid heart beat.

16. Which is more of a red flag, acute or chronic dyspnea?

Acute, sudden onset dyspnea is an acute red flag.

17. Croup leads to which type of breathing difficulty?

Inflammation of the trachea and the main-stem bronchi is known as croup, a common viral infection in young children, especially under the age of three, leading to problems with inspiration and the honking sound described in this chapter.

18. Asthma causes which type of breathing diffculty?

Patients with asthma have expiratory rather than inspiratory breathing difficulties, which present as wheezing attacks.

19. List the four types of parenchymal lung disease.

Pneumonia, bronchitis, interstitial fibrosis, and acute respiratory distress syndrome are parenchymal (diseases of the lung tissue itself).

20. Parenchymal lung diseases lead to interference with what normal physiologic function?

They interfere with proper exchange of oxygen and carbon dioxide.

21. What is the most common cause of plerual effusion, or the build-up of fluid in the pleural space? Name two diseases that may lead to pleural effusion.

Heart failure is the most common cause of a pleural effusion, but many other conditions can also cause it, including lupus, pneumonia, and conditions where there is a low concentration of protein in the blood.

22. Name four possible causes of increased respiratory drive ("air hunger.")

Anxiety, severe anemia, hormonal or neurological stimulation (such as hyperthyroidism), pregnancy, or exercise may all be causes.

23. "Surgical abdomen" is indicated by what two important symptoms?

Rebound tenderness with fever.

24. What signs would lead you to syspect gangrene?

Reddish or black discoloration of a finger, toe, or foot.

25. Gangrene can be seen in the case of what Western diseases?

Patients with diabetes mellitus, Raynaud's disease, perarteritis nodosa, Buerger's disease, or Behcet's disease.

26. With what symptom might a patient come for acupuncture treatment that you should refer for evaluation because it could lead to a pulmonary embolism?

Deep muscle pain in the lower leg.

27. What sign and symptom of the eye would lead you to an emergency referral to an ophthalmologist?

Redness of the conjunctiva associated with severe pain and/or alteration of vision.

28. Name three red flag Western medical conditions that may account for an unresolved chronic cough?

A chronic cough may be caused by lung cancer, lymphoma, heart failure, or a pleural effusion.

29. What are the most common signs and symptoms of infections of all kinds?

Fever and pain in the infected body part.

30. Why is chronic pain with unexplained weight loss a red flag?

It is a common symptom combination in many types of cancer.

31. Name and define the three types of irregular pulses discussed in Chinese pulse diagnosis. What do each of them mean in terms of Western medical diagnosis? What Chinese medical disease mechanisms does each one suggest?

The three skipped beat or irregular pulses are the skipping pulse, the bound pulse, and the regularly intermittant pulse.

1. The skipping pulse is rapid and irregularly irregular and either means that there is strong enough heat in the body that yin in unable to control or harmonize yang or that something is blocking the normal flow of the pulse (blood stasis or phlegm, for example) in addition to the heat. In Western medicine, this pulse is likely to indicate atrial fibrillation or atrial flutter.

2. The bound pulse is slow and irregularly interupted. In Chinese medicine,

the disease mechanisms that account for this are either yang qi vacuity (if it is a less forceful pulse) or obstruction (qi stagnation or blood stasis, for example) if it is a more forceful pulse. In Western medicine, this pulse indicates one or another type of cardiac arrythmia, and is considered a serious symptom that needs a complete cardiological workup.

3. The regularly intermittent pulse is slow and skips at regular intervals. It is almost always due to severe qi and or yang vacuity. In Western medical diagnosis, this is a serious pulse, often indicating congestive heart disease or possible heart failure.

32. Which is more worrisome, unilateral bleeding from one nipple or a bilateral non-bloody discharge? Why?

Bilateral breast discharge that is not bloody suggests a hormonal problem and should be evaluated by a gynecologist or endocrinologist. Unilateral discharge is more worrisome and suggests pathology in that breast, such as an infection or a tumor.

33. Name at least three neurological symptoms that could suggest the presence of a degenerative neurological disease.

Muscle weakness, loss of grip, numbness of the face or the extremities, double vision or other visual changes, sudden mood swings, the onset of a tremor, memory changes, or irrational or reckless behavior.

34. The onset of a fever of unknown origin usually indicates what?

Possibly tuberculosis, malignancy, or an infection of the lungs, urinary tract, or even bones.

35. While a new-onset of dizziness may or may not be serious, name as many of the potentially serious causes of this symptom as you can.

The new onset of such symptoms needs a medical workup as it might mean an impending stoke, heart trouble, or a possible brain tumor.